Contemporary Restorative Indications for the Use of Cast Gold: An Evidence-Based Perspective
Indications contemporaines pour l'utilisation des restaurations en or: une perspective fondée sur les preuves

By Dr. Mark A. Cruz, DDS

About the Author

Mark A Cruz graduated from the UCLA School of Dentistry in 1986 and started a dental practice in Monarch Beach, CA upon graduation. He has lectured nationally and internationally and is a member of various dental organizations including the Pierre Fauchard Academy, Pacific Coast Society for Prosthodontics and the American Academy of Restorative Dentistry. Until recently, he taught part-time at UCLA and was a member of the faculty group practice and was past assistant director of the UCLA Center for Esthetic Dentistry. He is currently on the editorial board as section editor for the Journal of Evidence Based Dental Practice (Elsevier). Please visit www.markacruzdds.com for a more detailed CV..

ABSTRACT

For decades, cast gold has been the standard, conservative indirect material of choice for restoring the posterior segment of the mouth when large direct restorations failed either due to recurrent caries, fractured cusps, patient reported symptoms of thermal sensitivity, or function. This reality was manifest by dental school curriculum, post-graduate education and licensure criteria. More recently in the past 1–2 decades, there has been an obvious shift away from the use of cast gold as reflected by changes in dental school curriculum and a progressive demand for "tooth-coloured" materials driving continuing-education courses and self-touted dental institutes as well as contemporary dental materials research. No doubt the public at large has had its awareness and demand increase for "cosmetic" restorations via "reality make-over" shows and magazine advertisement. The dentist's role in treatment planning the use of these materials as the perceived latest and greatest technologies has no doubt played a significant role with the public's awareness and demands. The purpose of this review is to discuss the major factors that may have resulted in the significant shift away from what the profession's standard had once been in restoring the posterior segment of the stomatognathic system. In addition, a proposal will be submitted in re-evaluating contemporary indications and contra-indications for the use of cast gold in the context of this review as well as current "best evidence".

Flawed dental dogma, a misunderstanding of how teeth, tooth structure and dental materials behave in function development of cosmetic" tooth-colored materials and market pressures are some of the major factors that have contributed to the decline of cast gold restorations in dentistry today.[1] The perception by the public at large regarding developing technology as well as the profession's will to constantly improve on established standards has also contributed to the oft-mistaken notion that novel technology is synonymous with better outcomes. No area in dentistry can demonstrate these notions better than in the development of tooth-colored materials. The profession's collective emotional and at times irrational mindset regarding novel ideas and developments has historically been demonstrated beginning with Michael Buonocore's introduction of the acid-etch technique in his paper published in 1967 with his seminal effort beginning in 1955 at the Eastman Dental Center.[2] The controversy this development stimulated within the profession at large is well known and not dissimilar to the controversy created within the medical profession

Figure 1

Figure 2

Figure 3

Figure 4

by Florence Nightingale's statistical tracking of post-operative infection. Both represented paradigm shifts that were difficult for their respective professions to accept as necessary changes in clinical practice. Since the advent of Buonocore's scientific contribution, the evolution of tooth-colored materials both bonded and un-bonded has continued unabated with some controversy. The posed controversy has existed mostly due to the conflict in values between "cosmetics" and predictable longevity statistically measured in decades versus mere months (Figures 1 and 2). Today the question regarding the use of tooth-colored restorative materials is not so much a matter of "if" these treatment alternatives are viable as much as "when" they serve the patient's best interest. The profession and the public at large would be better served if a more balanced approach would be considered when deciding which technique would best fulfill the patient's expectations, values and preferences. Both mindsets of "metal-free" dentistry and the inflexible use of indirect gold technique represent two sides of the same coin. Although cast gold technique represents a standard for longevity, function and comfort it does not represent a panacea for contemporary clinical practice. Tooth-colored options clearly fulfill the requirements of many clinical scenarios yet the experimental nature of many of these novel materials requires the conscientious clinician to divulge this reality to the patient as part of informed consent in comparison to the established "gold' standard.[3]

The following discussion will review some of the known factors that have contributed to the significant decrease in the use of indirect gold in the profession including flawed dental dogma, a lack of appreciation for the true nature of tooth tissue/structure behaviour in function and cosmetic driven influence in restorative choice. Rational suggestions for contemporary indications and contraindications for the use of indirect gold in contemporary modern practice will be made.

Flawed Dogma: Gold Inlays Fracture Teeth

The idea that cast gold inlays fracture teeth has been propagated as truth over the course of at least the last 30–40 years as stated in dental school textbooks and low level scientific evidence via in vitro lab bench studies.[4–6] Recent higher level evidence which will be discussed, strongly suggests otherwise.

Much of the flawed dogma regarding inlay mediated tooth fractures was based on

anecdotal clinical observation at a time where casting protocols were in a continuous evolution of development as well as a rudimentary understanding of dental tooth composition and structure. Although William H. Taggart first introduced the lost wax technique in 1907 and went on to develop a simple yet effective casting apparatus, others such as J.G. Lane and later C.S. VanHorn improved the accuracy of dental gold castings.[7] With more formalized dental school/university-based materials science, greater appreciation of the many intricacies in developing properly expanded, passive yet precise fitting castings continued. However, latent adoption and lack of universal appreciation of precise casting control is evident in much of the published literature[8] as described in the materials and methods sections where for example similar investment water: liquid ratios are utilized regardless of the casting design studied e.g., 2-surface, 3-surface, full coverage, etc.[9] As it turns out, these factors result in significant variability of casting fit and potential consequent stresses in the tooth/casting complexes as well as flawed study conclusions. Also, photoelastic studies used to support the notion that inlays behave as wedges are fundamentally flawed due to the inaccurate representation of tooth structure and resultant photo elastic stress/strain relationships. These "classic" studies have resulted in the erroneous concepts perpetuated in restorative dental text books used at least in part to inculcate the profession. For decades, restorative textbooks have commonly stated that cast inlays are retained by a "wedging" effect.[4] In actuality, when properly fabricated, dental castings are retained by an intimate adaption to the cavity preparation via a frictional fit from reciprocating axial surfaces with the luting agent further binding the complex together through cohesive energy. This outcome results in support of the remaining tooth structure and a favourable stress distribution within the tooth/casting complex. These outcomes are supported by clinical evidence that poses as significantly higher level evidence then the aforementioned in vitro bench studies.[10]

Finite-Element Analysis

More recently, finite-element analysis (FEA) studies have also resulted in a flawed representation of the behaviour of natural tooth structure.[11] The Young's modulus constants as well as Poisson's ratios of natural tooth tissues used to generate these studies have proven to be significantly inconsistent with the true modulus constants known today. Moreover, a lack of appreciation of the role of the dentino-enamel junction (DEJ) in providing the natural tooth with its resistance to flexure has been missed.[12,13] By virtue of the absence of the Young's modulus constant for the DEJ in recent FEA studies, the resultant conclusions regarding tooth tissue behaviour in function must be called into question in consideration for what we know currently. As an example, in Magne et al.'s study which evaluated tooth compliance/flexure after the removal of ⅓, ⅔ and complete removal of facial enamel, there was a dramatic increase in tooth flexure once the DEJ was compromised by complete removal of the facial enamel.[13] The experimental bench study used strain gauges on natural teeth to measure tooth flexure with an applied incisal load after the removal of ⅓, ⅔ and complete removal of the facial enamel. Although the increase in flexure was linear after the removal of the first and second thirds of facial enamel a significant non-linear inflection point was noted in the graphic representation of the experimental teeth once the remaining enamel was removed. This dramatic increase in tooth compliance/flexure after complete removal of the facial enamel was dismissed as an experimental artifact attributed to enamel crack propagation under the strain gauge affecting its signal. The FEA study that was run in parallel to collaborate the bench study as is commonly performed, resulted in a relatively linear increase in tooth compliance/flexure as well after the removal of the first 2 third increments and a smaller inflection once the enamel was completely removed. This result is attributed to the constants used and the omission of the DEJ's modulus, now known to confer significant resistance to flexure. The observations on the importance of the DEJ in resisting flexure and consequent fracture is collaborated by the most recent studies evaluating the mechanical properties of the human enamel and dentin.[11–15] The aforementioned comments are intended to emphasize the historical mischaracterization and flawed experimental observations on which didactic dogma has been perpetuated. As stated by Donald Maxwell Brunette, based on a positivist view of the world, empirical statements that describe the real world can be either true or false as a matter fact.[16] Decisions made based on false empirical statements are consequently likely to be erroneous. When involved in patient care, a re-evaluation of the evidence ought to be considered as prudent and rational.

The therapeutic replacement of lost tooth structure with a functional replacement that affords predictable long-term function can only be accomplished via a current and rigorous appreciation of its behaviour in function. In other words, a "bio-mimetic" replacement must be discussed in terms of functional biomechanics (resistance to fracture), physiologic wear of the opposing dentition and esthetic considerations. The exclusion of any of these 'bio-mimetic" factors may bias the optimal clinical outcome at the expense of the patient's preferences and values.

Hard tooth structure has been characterized as a composite material composed of enamel, mantle dentin and the DEJ. The surface hardness of enamel serves to function physiologically against the antagonist tooth structure and to protect the softer underlying DEJ and dentin complex. As it turns out, recent evidence suggests that, enamel is not the inherently brittle material it was once believed to be.

Enamel

The microstructure of enamel includes a configuration of apatite crystals and protein, enabling enamel to retain its structural integrity under cyclic loading for the life of the individual. Moreover, due to the shearing ability of the protein layers in enamel, it appears to behave more like a metal where the planes of atoms can slip over another under applied stresses enabling enamel to absorb a significant amount of energy prior to mechanical failure.[15] Thus, as a surrogate replacing enamel, it appears that this specific physical property of gold mimics nature (bio-mimetic) in regards to wear and fatigue more so than a brittle material such as ceramic or tooth-colored materials such as composite.[17] Due to the strong inter-atomic bonds present in ceramics, catastrophic failure characterizes brittle materials due to the limited ability to deform when absorbing energy in function.[15]

Additionally, it has been known to the point of

Figure 5

being self evident that dental ceramics causes more wear on the antagonist dentition than does gold alloy.[17] As suggested by Xie et al., dental materials with stress-strain responses similar to those of enamel may show less abrasiveness and better protective effects on the opposing dentition at least in part due to a reduction of stress concentration at functional contact points.[15] To date, gold alloys possess these biomechanic characteristics and ability to maintain form long term more so than any other material currently used in dentistry and therefore functionally harmonized best with the natural dentition.

Dentin/DEJ

Due to dentin being the most abundant tissue present in the human dentition, knowledge of its physical properties is important in understanding what material best serves as its substitute when it is lost due to caries, fracture or iatrogenic removal. Various restorative materials possess varied physical properties that dictate preparation design and indication.

The dentin that is protected by the harder enamel structure is what affords the dentition its resilience and toughness to function over a lifetime of cyclic mechanical challenge. Many of the concepts of the biomechanical properties of dentin have changed in the past 30 years.[11] For one, the magnitudes of the elastic constants are known to be significantly higher. The elastic constants (Young's) are measures of stiffness. Also, pre-existing flaws in dentin can cause teeth to fail at stresses far less than their theoretical strength. Therefore, dental restorative materials that confer stiffness become more predicable over time in restoring the replaced tooth structure (dentin, DEJ) and preserving long-term function. With all this in mind, we must set aside outdated dogmatic concepts that has influenced preparation design and indications for the use of cast gold.

As such it is important to understand that the all important junction between enamel and dentin, the DEJ acts to transfer functional loads from the enamel to the dentin and inhibits cracks in enamel from propagating and resulting in catastrophic fracture of the tooth. Imberni et al. have shown that cracks that are initiated in enamel are arrested after penetrating the DEJ within the mantle dentin (dentin adjacent to the optical DEJ).[13]

The greatest significance regarding strain values and stress distribution on the tooth in function is directly influenced by the quantity of tooth structure remaining and restorative material placed.[18–20]Therefore, conservation of tooth structure is of paramount importance in restoring long-term function. The lower the elastic modules of the restorative material used the less stiffness is imparted to the tooth resulting in greater flexure and consequent increased distribution of stresses to the tooth.[21]

Cosmetics

Over 40 years ago, Goldstein conducted a survey of 60 females ages 15–17 who were beauty pageant finalists and published his paper with the title "Study of Need for Esthetics in Dentistry." The author stated in his conclusions that when most of these young women asked their dentists for treatment advice related to cosmetics, the response was "it is not important" or "you look good enough."[22] Today, these responses would be considered inappropriate and insensitive. With that said, has the pendulum swung too far toward cosmetically driven dental treatment at the expense of function and longevity? Are these two values necessarily mutually exclusive? How much has the dental manufacturer influenced both patient and dentist in providing cosmetically driven dental care? How much of cosmetically-driven dental treatment has resulted in unnecessary health care cost? Running parallel to these questions are how much has the profession's previous lack of sensitivity toward the patients cosmetic preferences played a role in current market trends? Has the aforementioned discussion regarding didactic dogma as it pertains to iatrogenic tooth fractures played a contributory role in the decreased use of conservative gold castings? Has the prophylactic shoeing or onlaying of cusps to guard against cusp fracture as dictated by previous operative and prosthodontic principles narrowed the indication for cast gold to make it virtually irrelevant due to the cosmetic ramifications?

These are just a few questions that the conscientious dentist who is focused on the patient's overall well-being might consider, going forward. Also, in an era of evidence-based decision making, not only are we required to consider the best current evidence regarding our treatment recommendations but we are also to integrate the patient's preferences and values with the recommended treatment born out of accurate diagnosis and prognosis related issues.[23,24] In short, it is today's dental professional that has the responsibility of providing the patient with an informed consent due to the plethora of choices available many of which are still considered experimental. The "latest and greatest" is not synonymous with what is "best" for the patient but rather is more consistent with marketing influence. As defined by Beauchamp and Childress, an informed consent occurs if a patient, with substantial understanding intentionally authorized a professional to do something.[25] "Substantial understanding" requires that the patient be advised of the risks and benefits of each of the treatment alternatives. Although this process may take time beyond the mere execution of the procedure it does represent an important investment in the patient/doctor relationship and fosters trust that eclipses the necessary fiduciary event.

Few restorative situations are clear black and white decisions but rather more commonly reside in the grey. It may be well within the patient's values and rights to prefer a cosmetic outcome at the expense of duration of service if they are fully informed and intelligently accept the risks of their chosen alternative provided that the clinician is comfortable with the patient's decision. It does the profession,


Figure 6


Figure 7


Figure 8


Figure 9


Figure 10


Figure 11


Figure 12


Figure 13


Figure 14


Figure 15


Figure 16


Figure 17


Figure 18


Figure 19


Figure 20


Figure 21


Figure 22


Figure 23


Figure 24


Figure 25


Figure 26


Figure 27


Figure 28


Figure 29


Figure 30

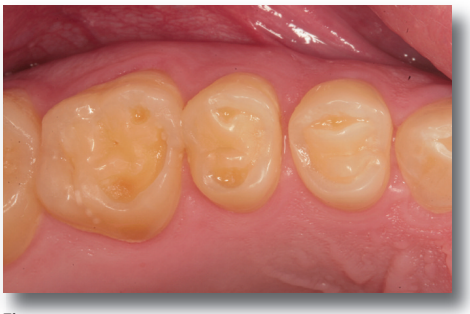
Figure 31


Figure 32


Figure 33


Figure 34

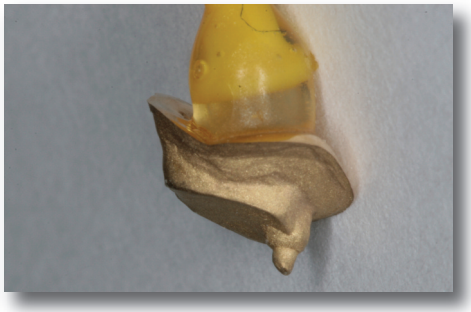
Figure 35


Figure 36


Figure 37


Figure 38


Figure 39


Figure 40


Figure 41


Figure 42

the patient, the clinician, and the utility of cast gold a disservice if the application of the cast gold technique is performed in the absence of the patient's informed acceptance. The argument can be equally made for the execution of any cosmetic restoration without the patient fully understanding and accepting the incurred risks and costs for both the short-term and long-term.[3,26] With the aim of perpetuating the value and relevance for advantages of cast gold in modern dental practice one may consider the following below as indications for the use of cast gold in this era of cosmetically driven treatment.

1. Whenever possible, eliminate the use of reverse bevels when shoeing non-functional cusps in the maxillary arch as they unnecessarily result in unesthetic outcomes (Figures 3-8).
2. Consider the use of cast gold as a long-term restorative alternative when replacing initial failure of direct filling restorations in lieu of waiting until the direct restoration is so large that it requires either extracoronal protection or full coverage restoration (Figures 9-13).
3. Consider the use of cast gold for restorations that are extensive enough to justify a conservative indirect restoration and that will remain esthetic with minimal to no display of gold from a conversational distance (Figures 14 and 15).
4. Consider using gold exclusively in maxillary and mandibular second molars,especially when full coverage is required, while educating the patient of the well-known benefits and minimal to irrelevant cosmetic considerations (Figures 16-20).
5. Avoid the use of cast gold in areas where display will be obvious unless the fully informed patient insists. Think about the cosmetic ramifications for the future use of indirect gold in a population that misunderstands or is unaware of the benefits of biocompatibility, comfort, longevity and physiologic wear at the expense of cosmetically driven values (Figures 21-26).
6. Consider using indirect gold with the young patient where restorations need to provide reliable service for decades, or where bacterial reservoirs under failing composites are being removed and where caries are managed by risk assessment

(Figures 27-30).

7. Consider using indirect gold when managing dental erosion after addressing the underlying etiology. Cast gold is best suited with the erosion patient due to favourable wear characteristics versus ceramic or composite. Centric stops are maintained long-term while eliminating the lack of predictability that comes from bonding to compromised tooth substrate (Figures 31–42).

Summary

With an evidence-based mindset where the use of current "best" evidence and clinical expertise can be integrated with the patient's values and preferences, today's clinicians have the significant responsibility of discerning what is best for the patient beyond mere dogma or market influence. This includes the fulfillment of not only cosmetic desires but also the well-established values of functional longevity, comfort and biocompatibility. By fulfilling one of these criteria at the expense of the other without the patient's true, informed consent clearly poses as an ethical breach in the doctor, patient relationship. Therefore, in the context of this review, an updated and current appreciation for and an understanding of the behaviour of the tooth/restoration complex is essential. Although the aforementioned statements are not novel concepts, a re-evaluation of our collective mindset when it comes to practice philosophy can only help the patient-centered clinician. What makes this action difficult to state and accept is the tendency to become entrenched and convinced that what we are doing in daily practice is beyond reproach. Taking the responsibility to "pass the torch" to the next generation of clinicians that have yet to develop "clinical expertise" and witness long-term clinical outcomes in the context of market influence, self-touted "gurus" and financial pressures is not a small order to accept. The spirit of the Hippocratic Oath makes it a given.

Conflicts

None declared.

References

1. Efrati A. new business for dentists: fixing botched cosmetic work. Wall Street Journal June 29, 2004; page B1.
2. Buonocore MG. Simple method of increasing the adhesive of acrylic filling materials to enamel surfaces, J Dent Res 34:849–53
3. Chambers DW. The ethics of experimenting in dental practice. Den Clin NA 2002;46:29–44
4. Pameijer JH. Tooth preparation, periodontal and occlusal factors in crown and bridge procedures. Dental Center for ostgraduate Courses, Holland 1985:204.
5. Shillingburg HT, Hobo S, Whitsett L Principles of preparation, fundamentals of fixed prosthodontics. Chicago: Quintessence Publishing Co. Chicago;1981:79.
6. Fisher DW, Caputo AA, Shillingburg HT, et al. Photo elastic analysis of inlay and onlay preparations. Oper Dent 175;33(1):47–53
7. Donaldson JA. The Use of Gold in Dentistry: An Historical Overview Part I. Gold Bulletin 117–24
8. Cruz MA, Sorenson JA, Johnson KA. Effect of venting and seating techniques on cementation of full gold castings. Oper Dent 2008;33(6):690–95.
9. Hembree JH, Cooper EW. Effect of die relief on retention of cast crowns and inlays. Oper Dent 1979;4:104–107
10. Donovan T, Simonsen RJ, Guertin, etal. Retrospective clinical evaluation of 1314 cast gold restorations in service from 1-52 years. J Esthet Restor Dent 2004;16(3):194–204
11. Kinney JH, Marshall SJ, Marshall GW. The mechanical properties of human dentin: A critical review and re-evaluation of the dental literature. Crit Rev Oral Bio Med 2003;14(1):13–29
12. Whit SN, Paine ML, Luow, etal. The dentino-enamel junction is a broad transitional zone uniting dissimilar bioceramic composites. J Am Ceram SOC 2000;83(1):238–40.
13. Imbeni V, Kruzic J, Marshall GW, et al. The dentin-enamel junction and the fracture of human teeth. Nature Materials 2005;5. Available at: www.nature.com/naturematerials.
14. Magne P, Versluis A, Douglas WH. Rationalization of incisor shape: Experimental-numerical analysis. J Prosthet Dent 1999 81(3):345–55
15. Xiez, Swain MV, Hoffman MJ. Structural Modeling. Sage journals online 2009. z.xie@ecu.edu.av.
16. Brunette DM. Critical thinking: Understanding and evaluating dental research. Carol Stream, IL: Quintessence Publishing Co, Inc; 60188:48.
17. Koczorowski R, Wlochs. Evaluation of wear of selected prosthetic materials in contact with enamel and dentin. J Prosthet Dent 1999;81:453–9
18. Soars PV, Santos-Filho P, Gomide HA, et al. Influence of restorative technique on the Biomechanical behavior of endodontically treated maxillary premolars. Part II: Strain measurement and stress distribution. J Prosthet Dent 2008;99:114–22
19. Soares PV, Santos-Filho, Martins L, et al. Influence of restorative technique on the biomechanical behavior of endodontically treated maxillary premolars. Part I: fracture resistance and fracture mode. J Prosthet Dent 2008;99:30–37.
20. Edelhoff D, Sorensen JA. Tooth structure removal associated with various preparation designs for anterior teeth. J Prosthet Dent 2002;87:503–9
21. Dejak B, Mlotkowski A. Three-dimensional finite element analysis of strength and adhesive of composite resin versus ceramic inlays in molars J Prosthet Dent 2008;99-131–40.
22. Goldstein RE. Study of need for esthetics in dentistry. J Prosth Dent 1969;21(6):589–98
23. Sackett, Straus, Richardson et al. Evidence-based medicine second edition; Philadelphia: Churchill Livingstone; 2000.
24. Cruz MA. Real-world implementation of evidence-based dental practice. J Evid Dent Pract 2006;6:121–24
25. Beauchamp TL, Childress JF. Respect for Autonomy In: Beauchamp TL, Childress JF. Principles of biomedical ethics, fourth edition New York: Oxford University Press; 1994.
26. Cruz MA, Evidence-based versus experienced-based decision making in clinical dentistry. J Amer Coll Dent 2000;67(1):11–14.